

## ORIGINAL ARTICLE

# The gold protocol: A combined treatment approach for neck rejuvenation with calcium hydroxyapatite, botulinum toxin, and hyaluronic acid in the same session

Carla de Sanctis Pecora MD 

Dermatologie Private Practice, São Paulo, Brazil

**Correspondence**

Carla de Sanctis Pecora, Avenida Dr. Cardoso de Melo, 1308, conj 121, Vila Olimpia, São Paulo-SP, CEP: 04548-004, Brazil.  
Email: [carla@dermatologie.com.br](mailto:carla@dermatologie.com.br)

**Funding information**

Merz Aesthetics

**Abstract**

**Background:** The signs of aging seem to be more visible on the neck compared to other locations, especially if a patient has already gone through facial rejuvenation procedures. Treatment of the aging neck imposes a challenge to the clinician, since one single approach is usually not enough to achieve the desired result, requiring multiple injections and sessions, which apart from being painful for the patients, is time-consuming for the clinician.

**Aim:** To describe the use of calcium hydroxyapatite, incobotulinum toxin type A and Cohesive poly-densified matrix hyaluronic acid diluted in the same syringe and injected in the same session for neck rejuvenation.

**Patients and Methods:** Fifteen women, older than 18 years, with cervical skin flaccidity grade 1–4 in a previously validated 5-point rating scale (*Dermatologic Surg*, 2016; 42, S94), who sought neck rejuvenation were injected in this pilot study with a single session with a combined hybrid mixture of calcium hydroxyapatite, incobotulinum toxin type A, and Cohesive poly-densified matrix hyaluronic acid and followed up for 90–180 days.

**Results:** At the 4-month post injection evaluation, 93.3% of the patients presented at least 1-grade improvement in the 5-point scale as evaluated by the investigator. No serious adverse events were reported, being most mild and transient in nature.

**Conclusion:** CaHA, incoBonTA, and CPM-HA have complementary mechanisms of action and may be injected from the same syringe in the same session, boosting the final outcome, with high patient satisfaction, and ease of process for both patients and clinicians.

**KEYWORDS**

botulinum toxin type A, calcium hydroxyapatite, hyaluronic acid, neck, rejuvenation

This is an open access article under the terms of the [Creative Commons Attribution](https://creativecommons.org/licenses/by/4.0/) License, which permits use, distribution and reproduction in any medium, provided the original work is properly cited.

© 2024 The Authors. *Journal of Cosmetic Dermatology* published by Wiley Periodicals LLC.

## 1 | INTRODUCTION

The signs of aging seem to be more visible on the neck compared to other locations, especially if a patient has already gone through facial rejuvenation procedures.<sup>1</sup> Years of exposure to extrinsic factors such as ultraviolet irradiation and pollution can further accelerate the intrinsic aging process. In fact, photoaging is believed to be accountable for almost 80% of the skin changes commonly attributed to the aging process,<sup>2</sup> clinically translated into pigmentation changes, poikiloderma of Civatte, solar lentigines, rough texture, and presence of telangiectasias. Other signs of cervical aging include volume loss, loss of the mandibular contour, prominence of the platysmal bands, accumulation of submental fat, and widening of the cervico-mental angle.<sup>1</sup>

From the surface to deep, neck layers include skin, subcutaneous or pre-platysmal fat, platysma muscle, subplatysmal fat, deep cervical fascia, and digastric muscles and submandibular glands.<sup>3</sup> Though aging may occur in all tissues, the onset and the speed of changes related to aging may differ for each structure and individual.<sup>4</sup> Reduction of collagen and elastin content of the skin is attributable to a decrease in synthesis and excessive breakdown by upregulated matrix metalloproteinases (MMPs).<sup>5</sup> A higher degree of calcification in elastin is observed in aged skin, with an associated degradation of elastin fibers.<sup>6</sup> Some muscles may become stronger because of a lifetime of overactivation, so that the muscle contraction forces the skin to fold along the same groove repetitively, leading a temporary wrinkle to convert to a persistent wrinkle.<sup>7,8</sup>

The interplay among the structures deep to the skin, and skin's ability to envelope them is what determine not only the aspect of the neck, but also the perception of an aged neck.<sup>9</sup> Moreover, aging neck patterns may vary and subjects with thin and long neck, good skeletal support, posterior and superiorly positioned hyoid, age better compared to those with short neck, poor mandibular support, and an inferiorly positioned hyoid, which results in an obtuse cervical-mandibular angle. For the latter cervical type, the outcomes after rejuvenating process are often suboptimal, due to the underlying anatomy. Therefore, a deep understanding of the anatomy and skin aging's physiologic process is vital when choosing best candidates for noninvasive neck rejuvenation.

Treatment of the aging neck imposes a challenge to the clinician, since one single approach is usually not enough to achieve the desired result. For instance, even though the platysma may play an important role in the development of cervical horizontal lines and in the facial contouring,<sup>10</sup> the use of botulinum toxin alone usually does not suffice to achieve a desirable cosmetic result. Moreover, treatment of the neck usually requires multiple injections and sessions. Combination of aesthetic therapies improves not only overall efficacy and time-to-result, but also provides a higher level of patient satisfaction, being particularly true for the neck, especially in the current era of the "impatient patient" and digital era, in which patients demand immediate health care.<sup>11,12</sup>

Notwithstanding many noninvasive aesthetic options exist to address the anatomical structural changes of different layers

individually (e.g., botulinum toxin for muscle, hyaluronic acid, or lasers for skin), literature concerning a combined approach to address changes in different layers in the same session is lacking. Thus, we sought to describe herein 15 clinical cases demonstrating the use of calcium hydroxyapatite, incobotulinum toxin, and cohesive hyaluronic acid diluted in the same syringe and injected in the same session for neck rejuvenation.

## 2 | MATERIALS AND METHODS

Cases treated in a pilot study with a combined technique for neck aging in São Paulo, Brazil were retrospectively analyzed. Eligible patients were men or women, older than 18 years, with cervical skin flaccidity grade 1–4 in a previously validated 5-point rating scale,<sup>13</sup> who sought neck rejuvenation and have provide consent to participate in the study.

Photographs were taken at baseline and after a follow-up interval of 90–180 days after the procedure. One subject, that presented a grade 4 in the cervical skin flaccidity scale, was followed up for 1 year after two sessions, with 4 months interval. For three subjects three-dimensional (3D) photographs were taken, using a digital camera (Vectra Software, Canfield, NJ, USA).

All procedures performed in this report involving human patients were in accordance with the 1964 Helsinki declaration and its later amendments or comparable ethical standards, as well as the ethical standards of the institutional and/or national research committee.

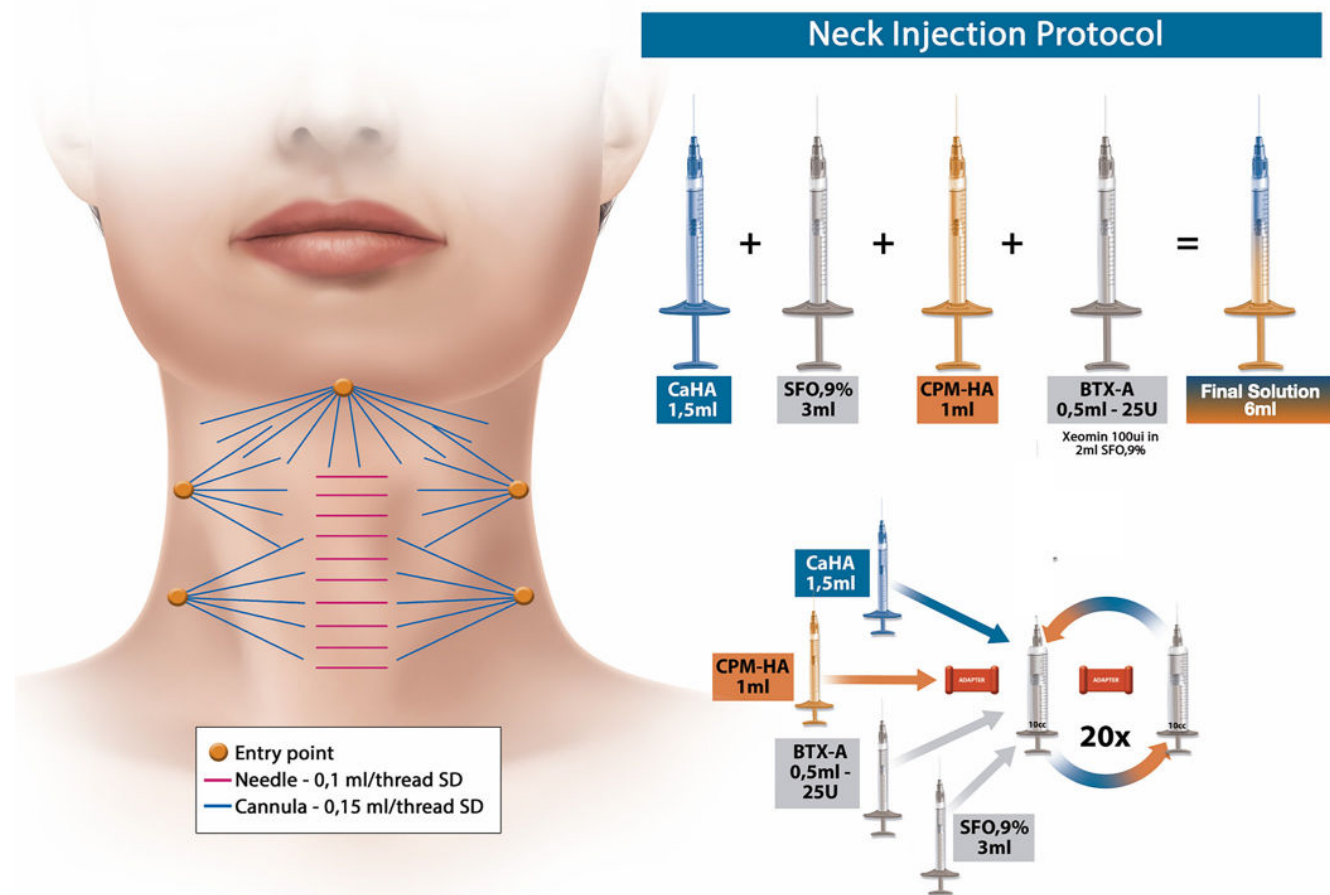
### 2.1 | Ethics approval

The report was approved by a centralized institutional review board (68035622.9.0000.80 54, approval date: July 28th, 2023). Written informed consent has been provided by all the patients.

### 2.2 | Technique

A vial of 100IU incobotulinum toxin (IncoBonTA; Xeomin®, Merz Pharmaceuticals GmbH, Frankfurt, Germany) was diluted with 2 mL of sterile saline solution.

One syringe of hyaluronic acid (1 mL; CPM-HA 22.5mg/ml; Belotero Balance Lido®; Cohesive poly-densified matrix hyaluronic acid; Merz Pharmaceuticals GmbH, Frankfurt, Germany), one syringe of calcium hydroxyapatite (1.5 mL; CaHA; Radiesse®; Merz Pharmaceuticals GmbH, Frankfurt, Germany), 0.5 mL (25 U) of the diluted incobotulinum toxin (100 U vial reconstituted in 2 mL of sterile saline solution), and 3 mL of sterile saline solution were transferred to a single 10 cc syringe, using a female transfer adaptor for a final volume of 6 mL and a CaHA dilution of 1:3 (Figure 1). A second 10 cc syringe should have enough volume to effortlessly accommodate the diluent and combined fillers and allow at least 20 passes between syringes to ensure product homogeneity



**FIGURE 1** Dilution and injection scheme: One syringe of CPM-HA—Belotero Balance® Lido (1 mL), one syringe of calcium hydroxylapatite—Radiesse® (1.5 mL) and 0.5 mL (25 U) of the diluted Incobotulinum toxin (100 U vial: 2 mL of sterile saline solution) and 3 mL of sterile saline solution are transferred to a 10 cc syringe, using a female transfer adaptor for a final volume of 6 mL and a CaHA dilution of 1:3. At least 20 passes between syringes should be performed to ensure product homogeneity. Suggested injection technique: Retrograde linear fanning pattern in the subdermal plane in the submental area and lateral parts of the neck.

(Figure 1). The combined blend should be used immediately after reconstitution, since it tends to separate quickly, especially at higher dilutions.

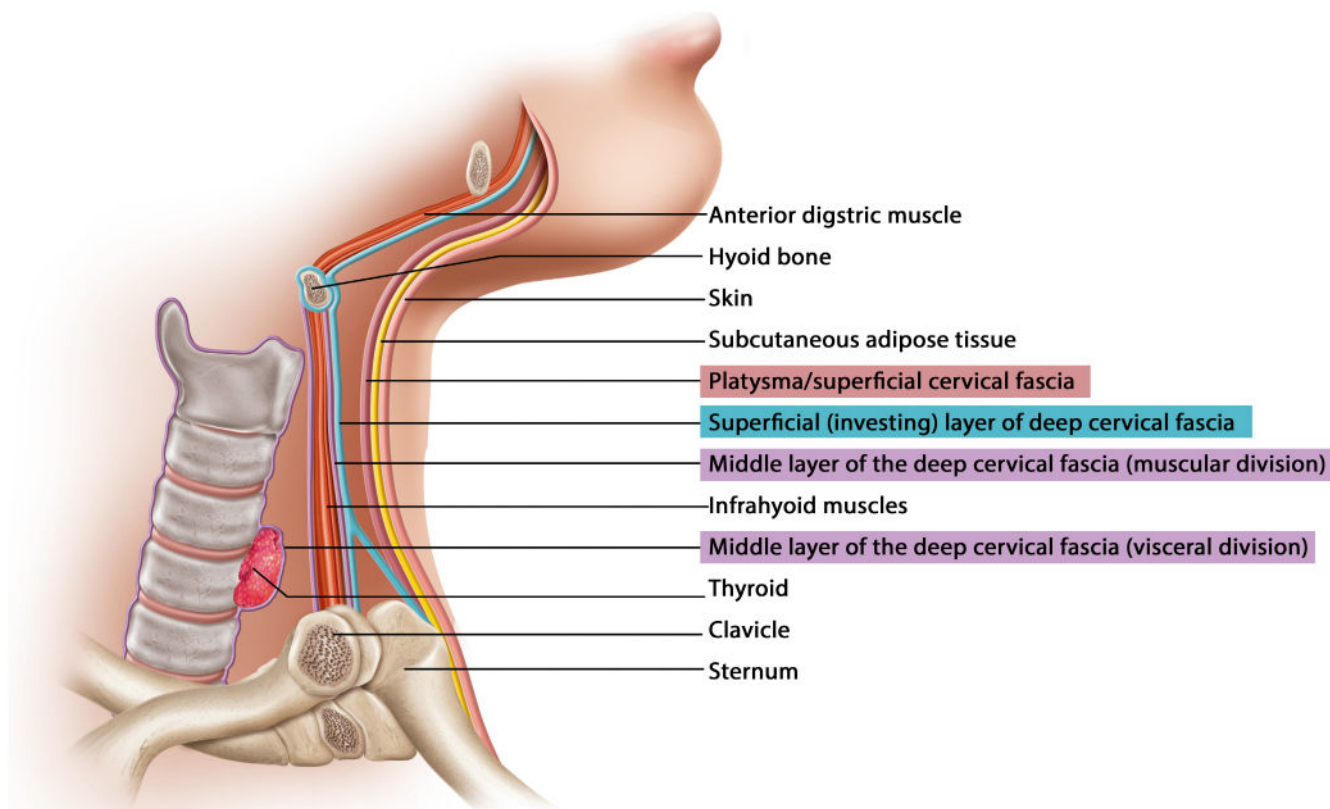
CPM-HA lidocaine already contains 2% lidocaine, so that there is no need of using lidocaine as the diluent or additional injectable anesthesia. Nevertheless, topical lidocaine cream can be applied in the entire area to be treated, while lidocaine 2% with epinephrine may be injected in the entry points to provide extra comfort to the patient.

The selection of the ideal plane of injection should consider the neck stratigraphy of interest (Figure 2).<sup>13</sup> The platysma originates at the deltopectoral fascia, crosses the mandibular border, being continuous with the superficial musculoaponeurotic system (SMAS) superiorly and separates the superficial subcutaneous fat and the deeper structures of the neck.<sup>9,14</sup> Since the superficial cervical fascia lays upon the platysma muscle, preserving this fascia's integrity is paramount to grant an avascular plane of dissection of the

subcutaneous fat.<sup>14</sup> The neck's fat compartments can be divided into: supraplatysmal fat (superficial, located between the platysma and the skin), which contains the most amount of fat; subplatysmal fat; and deep fat compartment, which contains the least amount of fat and located deep to the anterior digastric and submandibular glands.<sup>3</sup> It is of utmost importance to keep the injections in the subdermal plane in the superficial subcutaneous layer to avoid reaching deeper structures.

When considering the area of injection, the neck can be theoretically divided according to surface topography into anterior and posterior triangles. The anterior triangle, focus of our interest, is bounded inferiorly by the clavicles and external notch, superiorly by the chin and lower mandibular line and angle and laterally by the sternocleidomastoid muscle.<sup>9</sup>

While injecting it is important to avoid a few danger zones: in the posterior triangle of the neck, both the great auricular nerve and the external jugular vein run along the lateral aspect of the



**FIGURE 2** Neck stratigraphy of interest: from superficial to deep: skin, subcutaneous or pre-platysmal fat, platysma muscle, subplatysmal fat, deep cervical fascia, and the underlying digastric muscles and submandibular glands.

sternocleidomastoid muscle that is not covered by the platysma,<sup>9</sup> at an area in the mid-transverse belly of the sternocleidomastoid muscle, located approximately 6.5-cm inferior to the external auditory canal (Figure 3).<sup>15</sup> Moreover, superficial veins and anterior and external jugular veins and their tributaries travel underneath the platysma in the anterior-lateral portion of the neck. The facial nerve's cervical branch exits the inferior parotid gland, changing plane from deep to the parotid-masseteric fascia to a subplatysmal plane to innervate the platysma,<sup>9,14</sup> whereas the marginal mandibular nerve should be avoided around an area from the mandible angle to the corner of the mouth, 1 cm above and 2 cm below the mandible.<sup>16</sup>

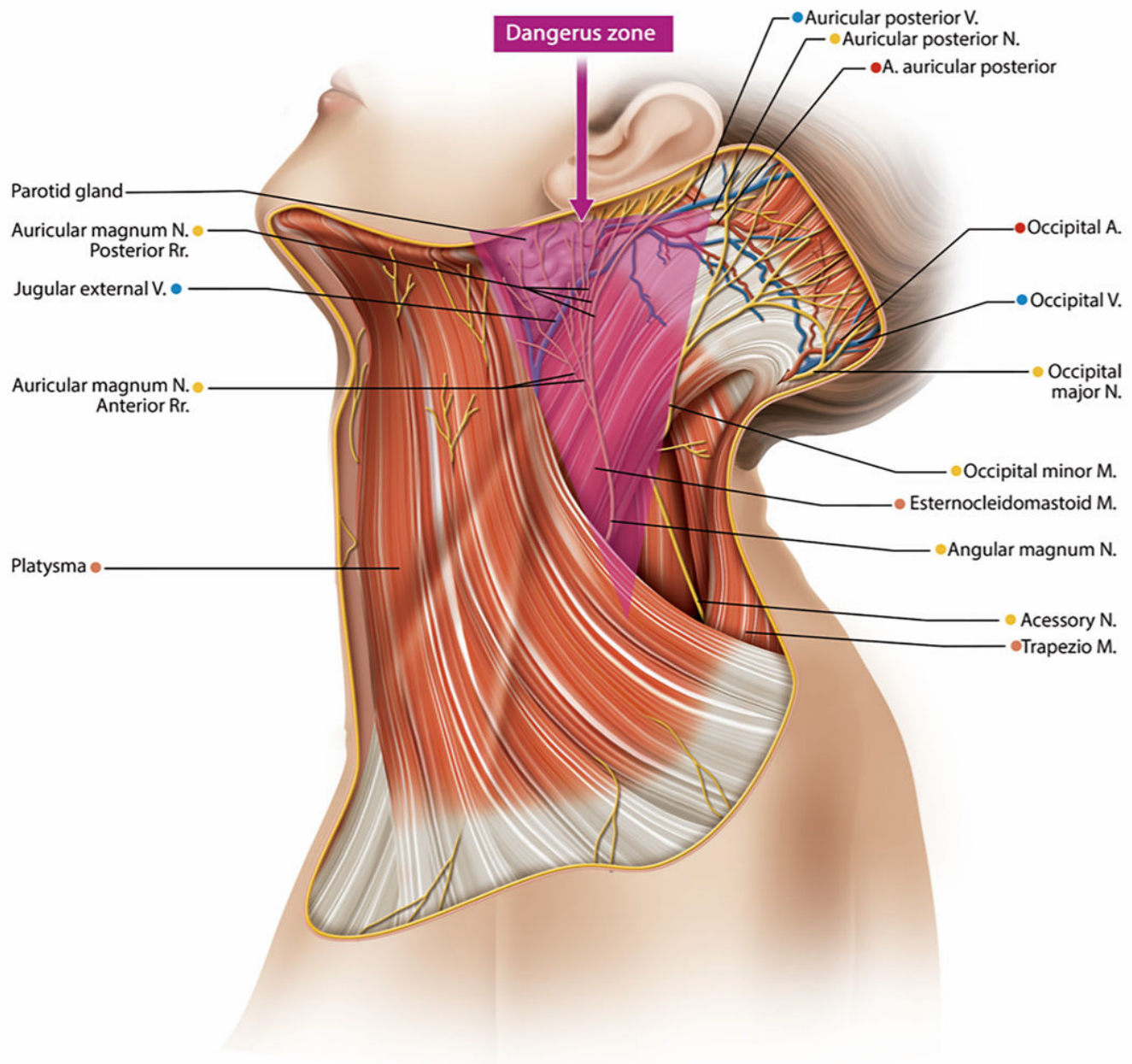
The detailed application scheme of the final mixture can be seen in Figure 1. On each side of the neck 2 entry points (five threads/entry point) were defined, close to the anterior border of the sternocleidomastoid m., and another one in the submental area (10 threads/entry point). The treatment was performed using the original 1.5 mL CaHA syringe, a 25 or 22G gauge canula, injecting retrograde linear threads (0.15 mL of the mixture/thread), in a fanning pattern in the subdermal plane, evenly distributing the final solution in the submental area and lateral parts of the neck. For the anterior part of the neck the injection was performed using a 30G needle in 10 parallel threads (0.1 mL/thread), also in the subdermal plane. Patients with a degree 3 or 4 in the cervical skin flaccidity scale

can be treated with the same injection protocol, although usually needed (two or three sessions with 4 months interval, respectively).

### 3 | RESULTS

Overall, 15 patients were enrolled, all being females, between 41 and 75 years of age (median age 53 years) and Fitzpatrick phototype I–III. No relevant medical history was reported (e.g., history of allergies, urticaria or angioedema, report of neurological diseases (e.g., myasthenia gravis, multiple sclerosis, history of upper eyelid ptosis or Bell's palsy or Eaton-Lambert syndrome), diabetes or connective tissue diseases; presence of hypertrophic scars or keloids, active infections or inflammatory processes in the area to be treated, or report of injectable procedure or facial or neck surgery within the last 12 months).

At baseline 46.6% were assessed as having severe cervical skin laxity in a 5-point scale,<sup>1</sup> while 26.6% were deemed as mild, 20% moderate and only one patient was regarded as having very severe skin laxity by the investigator. At the 4-month post injection evaluation, 93.3% of the patients presented at least 1-grade improvement in the 5-point scale as evaluated by the investigator. For one patient, no improvement was observed throughout the follow-up period.



**FIGURE 3** Cervical danger zones: anterior-lateral portion of the neck and lateral portion (posterior triangle) of the neck where the great auricular nerve and the external jugular vein run along the lateral aspect of the sternocleidomastoid muscle, not covered by the platysma.

After 15 days a lifting effect could be observed, with a progressive improvement in skin quality, horizontal lines, and laxity up to 120 days (grade 1 in 5-point rating cervical skin flaccidity scale). No serious adverse events were reported, being most adverse events deemed as mild and transient in nature (100% of the patients presented injection site ecchymosis).

#### 4 | DISCUSSION

Treatment of the aging neck imposes a challenge to the clinician, since one single approach is usually not enough to achieve the desired result. The skin is composed of multiple distinct viscoelastic

layers, in which wrinkles are formed through the folding of epidermis along with deformation of dermis.<sup>17,18</sup> The decline of the dermal collagen during skin aging renders less skin resilience under the same stress conditions, while reduction of elastic fibers result in impaired capacity of the skin to restore its shape once the stress is gone.<sup>17</sup> In young skin, temporary facial wrinkles are minimal, since the skin of a child is simply too resilient to form a groove during muscle contraction, whereas as skin laxity increases, the muscles may overpower the surrounding tissue resistance leading to wrinkle's appearance.<sup>7,8</sup>

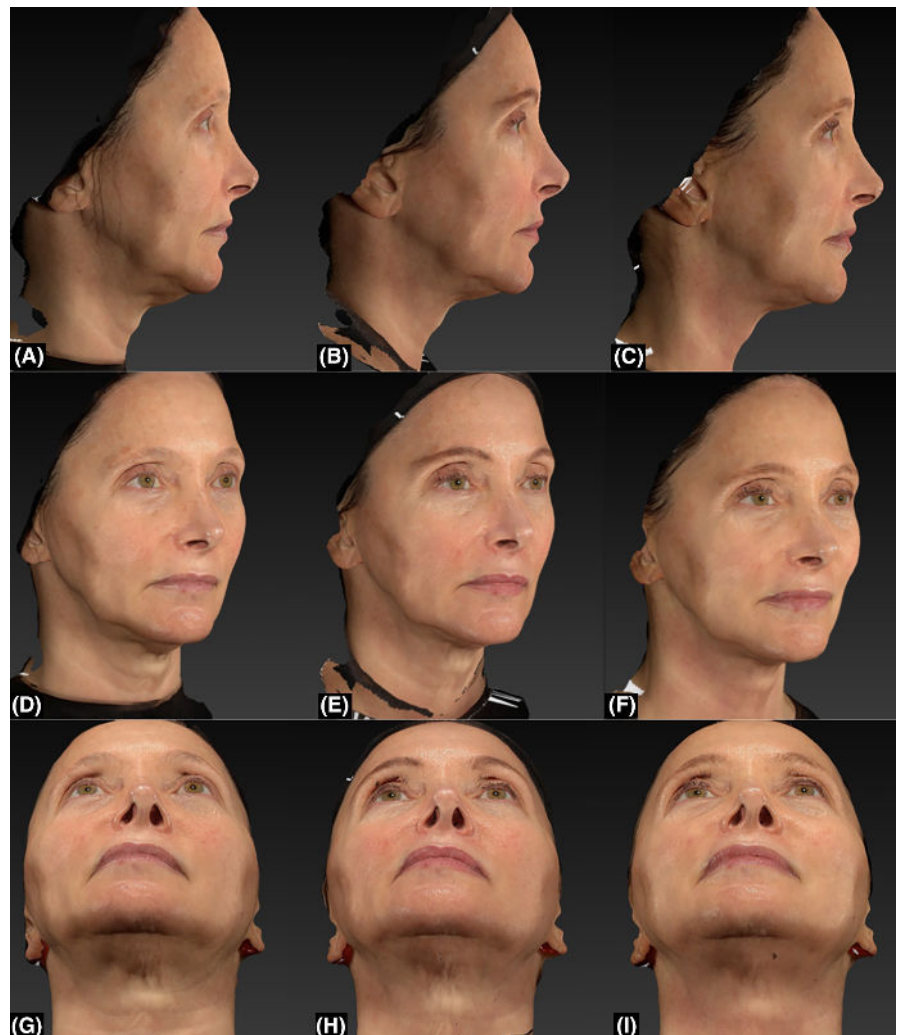In order to restore the delicate balance of the muscle contraction and the surrounding skin resistance, approach of both muscle and soft tissues seem to be plausible and necessary. Regular treatment with botulinum toxin type A, in an identical twin case study,

prevented the appearance of glabellar and frown lines secondary long-term muscle contraction compared to the untreated twin.<sup>19,20</sup> Moreover, delivery of multiple subdermal injections of incoBonTA to specifically weaken the superficial fibers of the muscles attached to the dermis smoothen horizontal creases, improve skin texture, vertical banding of the neck, as well as the contouring of the cervico-mental angle.<sup>21</sup> Furthermore, the advantage of superficial injections of BonTA, is that unwanted diffusion of the toxin into the deep neck structures is avoided, minimizing adverse events such as neck muscle weakness, dysphonia, and swallowing difficulties.<sup>22</sup>

On the soft tissue counterpart, improvement of the collagen and elastin content of the skin, aiming for skin laxity treatment, would be a reasonable approach and the main objective for CaHA use. Albeit hyaluronic acid (HA) may induce neocollagenesis by mechanical stretch of the surrounding tissue, CaHA lead to a more active remodeling of the extracellular matrix compared to HA, with increase in collagen and elastin synthesis.<sup>23,24</sup> CaHA microspheres seem to act as a regenerative scaffold for new tissue formation, fibroblast adherence, and activation,<sup>24</sup> leading to neocollagenesis process, where collagen type I gradually replaces collagen type III, with a peak in 4 months and a stability in 9 months.<sup>25,26</sup> Immunohistochemical data demonstrated significant increase in

collagen type I and III after hyperdiluted CaHA injection in neck and décolleté (1:2–1:6), correlating with improvements in skin elasticity and pliability evaluated by cutometry and increase in dermal thickness as evaluated by ultrasound.<sup>24</sup> Clinically, injection of hyperdiluted CaHA (1:2) was found to significantly improve the grading of the Neck Skin Laxity Scale (NSL) ( $p < 0.01$ ), while no major side effects were reported.<sup>27</sup> In a recent publication, a Brazilian group demonstrated that two sessions of subdermal hyperdiluted CaHA (1:4) were well-tolerated and improved necklines, neck laxity, and dermal thickness in adult women with mild and moderate cervical aging.<sup>28</sup> For horizontal necklines improvement, injections of HA should be performed at the immediate subdermal plane, with the ideal choice of product being a soft and spreadable HA. Due to its rheological properties of low viscous modulus and elastic moduli, and high tan delta,<sup>29</sup> CPM-HA is the ideal choice of product to avoid Tyndall effect and lumpiness, especially in the anterior neck where adipose tissue is lacking.<sup>30,31</sup> Significant improvement in wrinkle intensity was observed after CPM-HA injection in patients with horizontal neck wrinkles, throughout the study's 40-week follow-up.<sup>30</sup>

The downside of injecting each product at a time is that the patient has to undergo a myriad of injections, apart from being painful



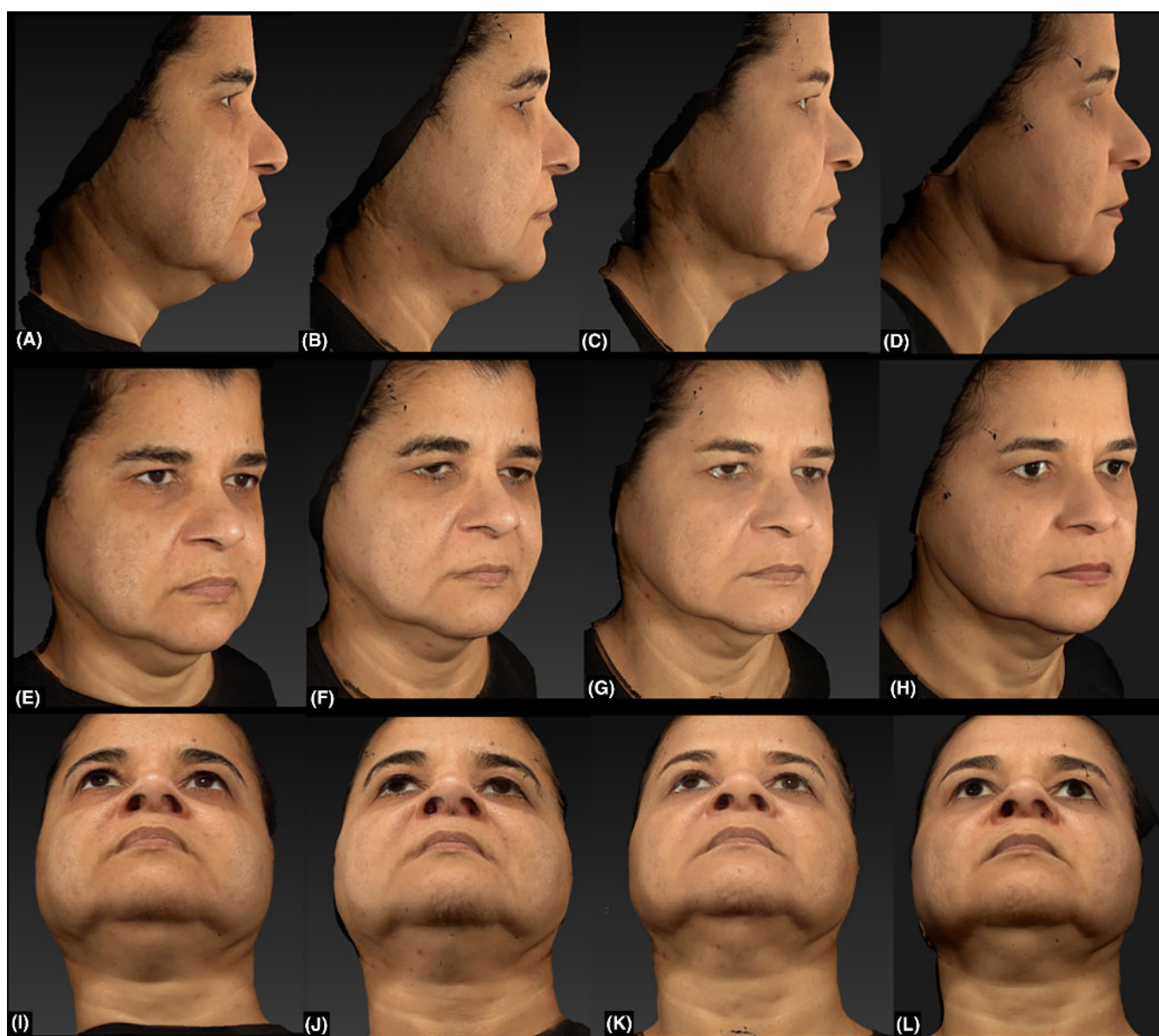
**FIGURE 4** 62-year-old female. Images taken with Vectra Software at baseline (A, D, G), 15 days (B, E, H), and 4 months after the treatment session (C, F, I).

for the patient<sup>22</sup> and time-consuming for the clinician. The use of hybrid combination of CaHA and a cohesive polydensified matrix HA (CaHA: CPM-HA) mix was previously reported,<sup>32,33</sup> as being safe in a cohort of 134 patients with a follow-up time of 1 year,<sup>34</sup> with 6-month skin biopsies from postauricular areas showing increased dermal collagen bundles without inflammation.<sup>35</sup> A "cocktail" of abobotulinumtoxinA, 2% lidocaine with 1:100000 epinephrine, and HA (Perlane, Medicis, Scottsdale, AZ) was previously described in periorcular and glabellar areas, with no compromise in efficacy and safety.<sup>36</sup> (Figure 4). No previous description of a mixture of IncoBonTA, hyaluronic acid, and calcium hydroxyapatite in the same syringe, injected in the same session was reported before. Nonetheless, the combined CaHA, IncoBonTA, and CPM-HA treatment does not compromise IncoBonTA efficacy since the effects of the hybrid mixture can be observed as early as 15 days after the procedure due to the

action of the neurotoxin in the superficial fibers of the platysma and the filling capacity of the CPM-HA (Figure 4).

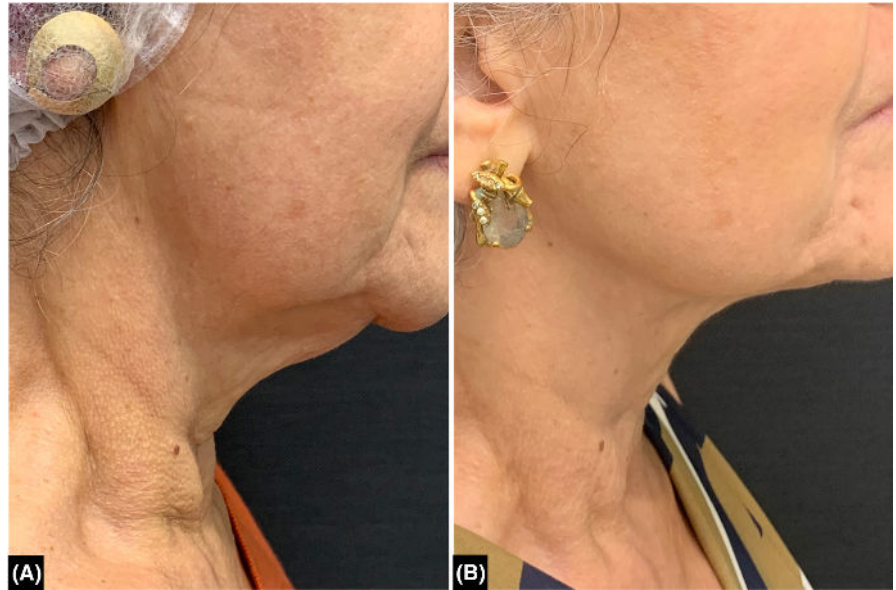We cannot rule out though, that the edema secondary to the trauma of the cannula and/or needle itself could have collaborated to the initial improvement. However, the lifting produced in the submental region after 15 days is most likely secondary to the action of IncoBonTA on the platysma. After 1 month some improvement can be observed because of the regenerative pathways induced by CaHA, and at 4 months the results were even better due to the expected peak of neocollagenesis induced by CaHA (Figures 4–6). Further studies are needed to validate the results presented herein.

Our study has limitations, as it was monocentric, lacked head-to-head controls, and the evaluation was performed by the investigator. Nevertheless, the clinical results and the near absence of adverse effects suggest that the proposed combined mixture may be safe and



**FIGURE 5** 50-year-old female. Images taken with Vectra Software at baseline (A, E, I), 15 days (B, F, J), 4 months (C, G, K), and 7 months after the treatment session (D, H, L).

**FIGURE 6** 75-year-old female. Images taken at baseline (A) and 5 months (B) after the treatment session.



effective for neck rejuvenation. Further evaluation in randomized, controlled trials with longer follow-up periods should be performed to corroborate the present results.

## 5 | CONCLUSION

Since CaHA, IncoBonTA, and CPM-HA have complementary mechanisms of action, and especially in the neck may be injected in the same layer, the combined treatment protocol including these three substances in the same syringe was proposed with the objective of achieving faster results, boost the final outcome, higher patient satisfaction, and ease the process for both patients and clinicians.

## ACKNOWLEDGMENTS

This research received no specific grant from any funding agency in the public, commercial, or not-for-profit sectors. Medical writing and editorial assistance were provided by Dr Danielle Shitara, (Private Practice), and was supported by Medical Affairs of Merz Aesthetics LATAM, through its affiliate Merz Farmaceutica Comercial Ltda, in accordance with Good Publication Practice guidelines.

## FUNDING INFORMATION

Merz Aesthetics funded medical writing assistance and provided products to this study through its affiliate in Brazil—Merz Farmacêutica Comercial Ltda. Despite this support, this study was conducted with autonomy and independence by the medical authors, and Merz Farmacêutica Comercial, Ltda. had any participation or influence on design, conduct, collect, assess and evaluate the presented data.

## CONFLICT OF INTEREST STATEMENT

Dr Pecora has been speaker for Merz Pharmaceuticals.

## DATA AVAILABILITY STATEMENT

The data that support the findings of this study are available on request from the corresponding author. The data are not publicly available due to privacy or ethical restrictions.

## ETHICS STATEMENT

The authors confirm that the ethical policies of the journal, as noted on the journal's author guidelines page, have been adhered to and the appropriate ethical review committee approval has been received. The case report was approved by a centralized institutional review board (68035622.9.0000.8054, approval date: July 28th, 2023). Written informed consent has been provided by all the patients to have the case details and any accompanying images published. All procedures performed in this report involving human patients were in accordance with the ethical standards of the institutional and/or national research committee and with the 1964 Helsinki declaration and its later amendments or comparable ethical standards.

## ORCID

Carla de Sanctis Pecora  <https://orcid.org/0000-0002-0711-281X>

## REFERENCES

1. Vanaman M, Fabi SG, Cox SE. Neck rejuvenation using a combination approach: our experience and a review of the literature. *Dermatologic Surg.* 2016;42(Suppl 2):S94-S100. doi:10.1097/DSS.0000000000000699
2. Bonte F, Girard D, Archambault JC, Desmouliere A. Skin changes during ageing. *Subcell Biochem.* 2019;91:249-280. doi:10.1007/978-981-13-3681-2\_10
3. Larson JD, Tierney WS, Ozturk CN, Zins JE. Defining the fat compartments in the neck: a cadaver study. *Aesthet Surg J.* 2014;34(4):499-506. doi:10.1177/1090820X14526406
4. Cotofana S, Fratila AA, Schenck TL, Redka-Swoboda W, Zilinsky I, Pavicic T. The anatomy of the aging face: a review. *Facial Plast Surg.* 2016;32(3):253-260. doi:10.1055/s-0036-1582234

5. Helfrich YR, Sachs DL, Voorhees JJ. Overview of skin aging and photoaging. *Dermatol Nurs*. 2008;20(3):177-183. quiz 184.
6. Farage MA, Miller KW, Elsner P, Maibach HI. Characteristics of the aging skin. *Adv Wound Care (New Rochelle)*. 2013;2(1):5-10. doi:[10.1089/wound.2011.0356](https://doi.org/10.1089/wound.2011.0356)
7. McKee D, Remington K, Swift A, Lambros V, Comstock J, Lalonde D. Effective rejuvenation with hyaluronic acid fillers: current advanced concepts. *Plast Reconstr Surg*. 2019;143(6):1277e-1289e. doi:[10.1097/PRS.00000000000005607](https://doi.org/10.1097/PRS.00000000000005607)
8. Hillebrand GG, Liang Z, Yan X, Yoshii T. New wrinkles on wrinkling: an 8-year longitudinal study on the progression of expression lines into persistent wrinkles. *Br J Dermatol*. 2010;162(6):1233-1241. doi:[10.1111/j.1365-2133.2010.09709.x](https://doi.org/10.1111/j.1365-2133.2010.09709.x)
9. Shadfar S, Perkins SW. Anatomy and physiology of the aging neck. *Facial Plast Surg Clin North Am*. 2014;22(2):161-170. doi:[10.1016/j.fsc.2014.01.009](https://doi.org/10.1016/j.fsc.2014.01.009)
10. de Almeida ART, Romiti A, Carruthers JDA. The facial platysma and its underappreciated role in lower face dynamics and contour. *Dermatologic Surg*. 2017;43(8):1042-1049. doi:[10.1097/DSS.0000000000001135](https://doi.org/10.1097/DSS.0000000000001135)
11. Heden P, Hexsel D, Cartier H, et al. Effective and safe repeated full-face treatments with AbobotulinumtoxinA, hyaluronic acid filler, and skin boosting hyaluronic acid. *J Drugs Dermatol*. 2019;18(7):682-689.
12. Forkner-Dunn J. Internet-based patient self-care: the next generation of health care delivery. *J Med Internet Res*. 2003;5(2):e8. doi:[10.2196/jmir.5.2.e8](https://doi.org/10.2196/jmir.5.2.e8)
13. Vaca E, Sinno S. Rejuvenation of the neck. *Advances in Cosmetic Surgery*. 2018;1(1):23-30. doi:[10.1016/j.yacs.2018.02.019](https://doi.org/10.1016/j.yacs.2018.02.019)
14. Friedman O, Shamban A, Fabi S, Duncan DI, Artzi O. The aging neck-a case base treatment algorithm. *J Cosmet Dermatol*. 2021;20(2):569-576. doi:[10.1111/jocd.13877](https://doi.org/10.1111/jocd.13877)
15. Calisti A, Elattar A. Three-dimensional vision: circumferential non-surgical neck rejuvenation. *Dermatologic Surg*. 2017;43(9):1186-1189. doi:[10.1097/DSS.0000000000001089](https://doi.org/10.1097/DSS.0000000000001089)
16. Owsley JQ, Agarwal CA. Safely navigating around the facial nerve in three dimensions. *Clin Plast Surg*. 2008;35(4):469-477, v. doi:[10.1016/j.cps.2008.05.011](https://doi.org/10.1016/j.cps.2008.05.011)
17. Choi JW, Kwon SH, Huh CH, Park KC, Youn SW. The influences of skin visco-elasticity, hydration level and aging on the formation of wrinkles: a comprehensive and objective approach. *Skin Res Technol*. 2013;19(1):e349-e355. doi:[10.1111/j.1600-0846.2012.00650.x](https://doi.org/10.1111/j.1600-0846.2012.00650.x)
18. Magnenat-Thalmann N, Kalra P, Leveque JL, Bazin R, Batisse D, Querleux B. A computational skin model: fold and wrinkle formation. *IEEE Trans Inf Technol Biomed*. 2002;6(4):317-323. doi:[10.1109/titb.2002.806097](https://doi.org/10.1109/titb.2002.806097)
19. Binder WJ. Long-term effects of botulinum toxin type a (Botox) on facial lines: a comparison in identical twins. *Arch Facial Plast Surg*. 2006;8(6):426-431. doi:[10.1001/archfaci.8.6.426](https://doi.org/10.1001/archfaci.8.6.426)
20. Rivkin A, Binder WJ. Long-term effects of onabotulinumtoxinA on facial lines: a 19-year experience of identical twins. *Dermatologic Surg*. 2015;41(Suppl 1):S64-S66. doi:[10.1097/DSS.0000000000000193](https://doi.org/10.1097/DSS.0000000000000193)
21. Wu WTL. Microbotox of the lower face and neck: evolution of a personal technique and its clinical effects. *Plast Reconstr Surg*. 2015;136(5 Suppl):92S-100S. doi:[10.1097/PRS.0000000000001827](https://doi.org/10.1097/PRS.0000000000001827)
22. Awaida CJ, Jabbour SF, Rayess YA, El Khoury JS, Kechichian EG, Nasr MW. Evaluation of the Microbotox technique: an algorithmic approach for lower face and neck rejuvenation and a crossover clinical trial. *Plast Reconstr Surg*. 2018;142(3):640-649. doi:[10.1097/PRS.0000000000004695](https://doi.org/10.1097/PRS.0000000000004695)
23. Yutskovskaya Y, Kogan E, Leshunov E. A randomized, split-face, histomorphologic study comparing a volumetric calcium hydroxylapatite and a hyaluronic acid-based dermal filler. *J Drugs Dermatol*. 2014;13(9):1047-1052.
24. Yutskovskaya YA, Kogan EA. Improved neocollagenesis and skin mechanical properties after injection of diluted calcium hydroxylapatite in the neck and décolletage:a pilot study. *J Drugs Dermatol*. 2017;16(1):68-74.
25. Goldie K, Peeters W, Alghoul M, et al. Global consensus guidelines for the injection of diluted and hyperdiluted calcium hydroxylapatite for skin tightening. *Dermatologic Surg*. 2018;44(Suppl 1):S32-S41. doi:[10.1097/DSS.0000000000001685](https://doi.org/10.1097/DSS.0000000000001685)
26. de Almeida AT, Figueredo V, da Cunha ALG, et al. Consensus recommendations for the use of hyperdiluted calcium hydroxylapatite (Radiesse) as a face and body biostimulatory agent. *Plast Reconstr Surg Glob Open*. 2019;7(3):e2160. doi:[10.1097/GOX.0000000000002160](https://doi.org/10.1097/GOX.0000000000002160)
27. Guida S, Longhitano S, Spadafora M, et al. Hyperdiluted calcium hydroxylapatite for the treatment of skin laxity of the neck. *Dermatol Ther*. 2021;34(5):e15090. doi:[10.1111/dth.15090](https://doi.org/10.1111/dth.15090)
28. Trindade de Almeida AR, Marques E, Contin LA, Trindade de Almeida C, Muniz M. Efficacy and tolerability of hyperdiluted calcium hydroxylapatite (Radiesse) for neck rejuvenation: clinical and ultrasonographic assessment. *Clin Cosmet Investig Dermatol*. 2023;16:1341-1349. doi:[10.2147/CCID.S407561](https://doi.org/10.2147/CCID.S407561)
29. Santoro S, Russo L, Argenzio V, Borzacchiello A. Rheological properties of cross-linked hyaluronic acid dermal fillers. *J Appl Biomater Biomech*. 2011;9(2):127-136. doi:[10.5301/JABB.2011.8566](https://doi.org/10.5301/JABB.2011.8566)
30. Tseng F, Yu H. Treatment of horizontal neck wrinkles with hyaluronic acid filler: a retrospective case series. *Plast Reconstr Surg Glob Open*. 2019;7(8):e2366. doi:[10.1097/GOX.0000000000002366](https://doi.org/10.1097/GOX.0000000000002366)
31. Corduff N, Chen JF, Chen YH, et al. Pan-Asian consensus on calcium hydroxylapatite for skin biostimulation, contouring, and combination treatments. *J Clin Aesthet Dermatol*. 2021;14(8):E76-E85.
32. Moradi A, Shirazi A, David R. Nonsurgical Chin and jawline augmentation using calcium hydroxylapatite and hyaluronic acid fillers. *Facial Plast Surg*. 2019;35(2):140-148. doi:[10.1055/s-0039-1683854](https://doi.org/10.1055/s-0039-1683854)
33. Yag-Howard C, DeNigris J. Novel filler technique: hyaluronic acid and calcium hydroxylapatite mixture resulting in favorable aesthetic and longevity outcomes. *Int J Womens Dermatol*. 2021;7(5 Pt B):817-819. doi:[10.1016/j.ijwd.2021.09.008](https://doi.org/10.1016/j.ijwd.2021.09.008)
34. Fakh-Gomez N, Kadouch J. Combining calcium hydroxylapatite and hyaluronic acid fillers for aesthetic indications: efficacy of an innovative hybrid filler. *Aesth Plast Surg*. 2022;46(1):373-381. doi:[10.1007/s00266-021-02479-x](https://doi.org/10.1007/s00266-021-02479-x)
35. Chang JW, Koo WY, Kim EK, Lee SW, Lee JH. Facial rejuvenation using a mixture of calcium hydroxylapatite filler and hyaluronic acid filler. *J Craniofac Surg*. 2020;31(1):e18-e21. doi:[10.1097/SCS.00000000000005809](https://doi.org/10.1097/SCS.00000000000005809)
36. Kenner JR. Hyaluronic acid filler and botulinum neurotoxin delivered simultaneously in the same syringe for effective and convenient combination aesthetic rejuvenation therapy. *J Drugs Dermatol*. 2010;9(9):1135-1138.

**How to cite this article:** de Sanctis Pecora C. The gold protocol: A combined treatment approach for neck rejuvenation with calcium hydroxylapatite, botulinum toxin, and hyaluronic acid in the same session. *J Cosmet Dermatol*. 2024;23:2392-2400. doi:[10.1111/jocd.16296](https://doi.org/10.1111/jocd.16296)